



available at [www.sciencedirect.com](http://www.sciencedirect.com)



journal homepage: [www.elsevierhealth.com/journals/trst](http://www.elsevierhealth.com/journals/trst)



# A first report of pulmonary melioidosis in Cambodia

Rob Overtoom<sup>a,b\*</sup>, Virak Khieu<sup>b</sup>, Sopheak Hem<sup>b</sup>, Philippe Cavailler<sup>b</sup>,  
Vantha Te<sup>c</sup>, Sarin Chan<sup>b</sup>, Phea Lau<sup>c</sup>, Bertrand Guillard<sup>b</sup>, Sirenda Vong<sup>b</sup>

<sup>a</sup>Swiss Red Cross, Takeo, Cambodia

<sup>b</sup>Institut Pasteur in Cambodia, Phnom Penh, Cambodia

<sup>c</sup>Takeo Provincial Hospital, Takeo, Cambodia

## KEYWORDS

Melioidosis  
*Burkholderia pseudomallei*  
Laboratory techniques and procedures  
Antibiotics  
Case report  
Cambodia

**Summary** Melioidosis has never been officially reported from Cambodia. Here we report two cases, a 58-year-old male (case 1) and a 49-year-old female (case 2) who presented with respiratory illnesses featuring multiple lung abscesses. The sputum culture of both patients, taken in the framework of a laboratory-based study on aetiologies of (sub-)acute respiratory infections among hospitalized patients in southern Cambodia, grew *Burkholderia pseudomallei*. The most striking aspect of these case stories was the extent of the delays in diagnosis. Presenting with a 1-month history of respiratory symptoms, case 1 was first suspected of tuberculosis (TB) infection, and then misdiagnosed as 'metastatic lung cancer' in Phnom Penh, Cambodia. Case 2 suffered from pulmonary infections for >10 years, during which time she was treated for TB four times. Neither patient ever produced acid-fast-bacilli (AFB)-positive sputum. Following our laboratory confirmation, the patients were traced for re-admission. Under the 'classical' trimethoprim-sulphamethoxazole, chloramphenicol and doxycycline treatment, their clinical status improved considerably within 2 weeks. The two study cases illustrate issues relating to the misdiagnosis of melioidosis in Cambodia; an unfamiliarity of clinicians with the disease, which is associated with a high prevalence of TB. Therefore, a heightened awareness of melioidosis among clinicians would have a substantial impact on public health as the non-septicaemic form of the disease is potentially treatable with antibiotics that are available in Cambodian public hospitals.

© 2008 Published by Elsevier Ltd on behalf of Royal Society of Tropical Medicine and Hygiene.

## 1. Introduction

With melioidosis known to be endemic in Southeast Asia and northern Australia, and being a recognized public health issue in the countries bordering Cambodia, it is likely that melioidosis is severely under-diagnosed in Cambodia. In the more developed countries in Southeast Asia such as Thailand, Malaysia, Singapore and in northern Australia, the disease is extensively reported; cases from Laos have only been reported since 2001, and from Burma, where the disease was discovered in 1911, a 're-emergence' was reported during the 5th World Conference on Melioidosis in Khon Kaen, Thailand in 2007.

Melioidosis in Cambodian patients has been diagnosed in a few cases in Cambodia, but to our knowledge, it has never officially been documented. In Cambodia there are currently only three facilities where *Burkholderia*

*pseudomallei* is isolated from patients; the Institut Pasteur du Cambodge (IPC) in Phnom Penh, the Angkor Hospital for Children in Siem Reap, and the Center of Hope in Phnom Penh. In April 2007, the IPC initiated a surveillance of pneumonias in the Takeo Provincial Hospital, a province some 85 km south of Phnom Penh, in which specimens from patients can now be cultured; this is the first public hospital where specimens can be cultured.

Awareness of melioidosis amongst medical professionals in Cambodia is very low. However, recognition of the disease in Cambodia is important for several reasons, the two most important being (i) the pulmonary form of the disease often mimics pulmonary tuberculosis (TB) (in the clinical presentation and X-ray films), a disease that is diagnosed on a daily basis in hospitals all over the country, and (ii) diabetes is identified as the most common underlying ailment of patients suffering from melioidosis, and surveys have shown that diabetes is found in a surprisingly high percentage of Cambodians.<sup>1</sup>

\* Corresponding author.

Tel.: +855 12 914 441; fax: +855 23 725 606.

E-mail address: [overtoom.r@gmail.com](mailto:overtoom.r@gmail.com) (R. Overtoom).

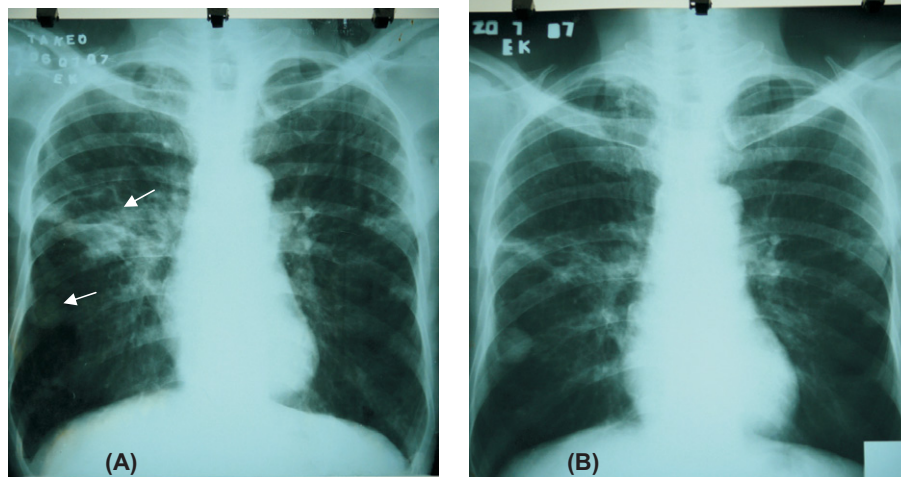


Fig. 1. Chest radiographs of case 1: (A) on re-admission; (B) on day 14 of treatment with trimethoprim-sulphamethoxazole, chloramphenicol and doxycycline.

## 2. Patients and methods

The hospital-based study of aetiologies of community-acquired acute respiratory infections has been set up by the IPC since April 2007 in the Provincial Hospital of Takeo province. The essential objectives of the surveillance are: (i) to strengthen the laboratory capacity in bacteriology and virology of Provincial Hospitals (a second site opened in Kompong Cham in the beginning of 2008), and (ii) to study the aetiologies of (sub-)acute respiratory infections among hospitalized patients in public hospitals in Cambodia. As a result of the surveillance, proper up-to-date diagnostic possibilities are suddenly available to the clinicians in the Takeo Hospital. Patients with the following criteria are eligible for the study: a fever of  $\geq 38^{\circ}\text{C}$  or a history of feverish episodes during the last 3 days, plus at least one of the following key respiratory symptoms – cough, expectoration or sputum production, or difficulty in breathing (shortness of breath). Specimens taken for analysis include pharyngeal and nasal swabs, sputum culture, blood culture and urine sample. We report two cases, a 58-year-old male (case 1) and a 49-year-old female (case 2) who gave written consent and who were treated with medication at the disposal of the clinicians in the Takeo Provincial Hospital. The strains of *B. pseudomallei* isolated from the two patients showed almost identical sensitivity/resistance to the antibiotics routinely tested for in the IPC. The strain isolated from case 2 was tested with trimethoprim-sulphamethoxazole, chloramphenicol and doxycycline, and showed to be sensitive for all three antibiotics.

## 3. Results

### 3.1. Case 1

The first patient, a 58-year-old male rice farmer, presented with a 1-month history of fever, cough, chest pain, difficulty in breathing, headache, and weight loss. On admission, the patient was noted to be mildly febrile ( $38^{\circ}\text{C}$ ), and examination of his lungs revealed crepitations in both lungs. He had a productive cough and complained of dyspnoea. No predisposing condition such as diabetes mellitus or chronic

renal disease could be identified. A first chest radiograph in the provincial hospital showed a bilateral pneumonia with multiple abscesses and an irregular, thin-walled cavity of around 5 cm diameter in the right lung with a fluid level, indicating an open connection with the bronchial tree (Figure 1A). Haematological and biochemical analyses did not show significant abnormalities. As the patient was included in the surveillance project on community-acquired pneumonia, blood and expectoration specimens, nasopharyngeal and throat swabs and urine samples were collected and sent for testing at the IPC in Phnom Penh. The working diagnosis was bilateral pneumonia, and he was given 4 d of antibiotic treatment (azithromycin). On this regimen the patient did not improve, and he was referred to Phnom Penh for further investigation of the presumptive 'metastatic lung tumour' diagnosis that was given on discharge.

After the result of his sputum culture in the IPC came back to the Takeo Hospital, the patient was traced in his village. He had returned there as the discharge diagnosis 'metastatic tumour in the lungs' was 'confirmed' in Phnom Penh. The patient did not have enough money for the treatment, which made him decide to return home and as a last resort try herbal treatment provided by the traditional healer in his village. He was persuaded to return to the Takeo Hospital, where he was re-admitted and started on the 'classical' trimethoprim-sulphamethoxazole, chloramphenicol and doxycycline treatment regimen for melioidosis. A follow-up X-ray taken on day 14 of treatment showed the lungs had cleared significantly and the cavity was reduced to 3 cm (Figure 1B). The patient was discharged on his request to continue treatment at home, was given trimethoprim-sulphamethoxazole and doxycycline for 2 weeks and was asked to return in 2 weeks for control and refill of medication. On discharge he was without fever, his cough had subsided, he had gained 3 kg in weight and felt much better.

### 3.2. Case 2

The second patient, a 49-year-old mother of seven, developed a productive cough, fevers and weight loss during the third trimester of her last pregnancy, more than 10

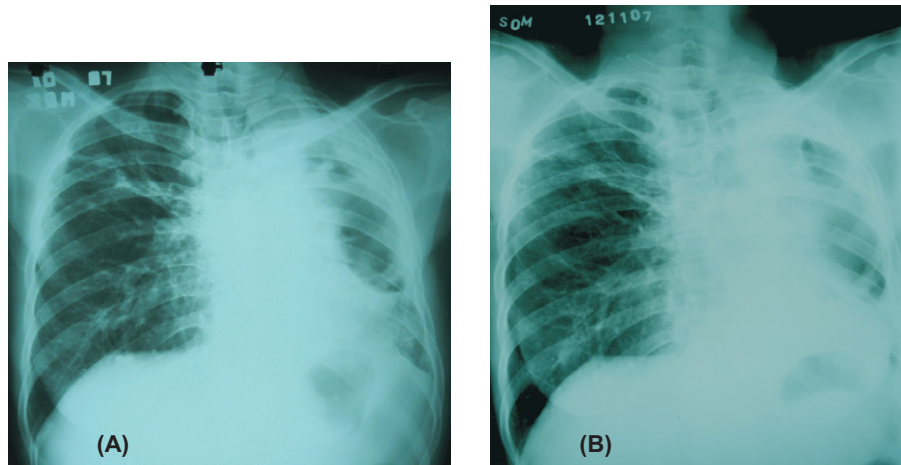


Fig. 2. Chest radiograph of case 2: (A) on re-admission; (B) on day 14 of treatment with trimethoprim–sulphamethoxazole, chloramphenicol and doxycycline.

years ago. She was treated for pulmonary TB, improved a bit and went home, but the infection did not go away. She suffered in total for more than 10 years (during which period the family sold two plots of rice-land and one cow to pay for her treatments) before she was diagnosed with pulmonary melioidosis. It is of course not said that she suffered from pulmonary melioidosis during all these years, but as she did not show any of the known predisposing conditions, she might have become susceptible as a result of her diminishing immune system during the third trimester of her pregnancy; a condition that is not described to be pre-disposing for melioidosis infection, but possibly could be considered as such, especially in poor countries where pregnant women stay involved in the farming process (and exposed to *B. pseudomallei*) until just before delivery.

During these 10 years she was treated four times for pulmonary TB, as she presented with weight loss, fevers, productive cough and dyspnoea, while the lung X-ray showed an infection with cavities, making the treating medical personnel think she had suffered from pulmonary TB. She arrived with a history of a 10-d productive cough and shortness of breath. On admission she weighed 34 kg, was dyspnoeic and had a fever (39.5°C). A chest X-ray made on re-admission (Figure 2A) showed cavitations in her left lung and deviation of the trachea to that side: an indication of scar retraction. The right lung also showed signs of long-term involvement.

Her blood examination only showed a mild anaemia (9.9 g/dl; N: 11.0–16.5) and her serum glutamic pyruvic transaminase (SGPT) level was slightly elevated (48 U/l; N: ≤35 U/l). Her lung exam revealed diminished breath-sounds and crepitations over her left lung. She was treated with amoxicillin but did not improve on this medication and was referred to Phnom Penh after a few days for further diagnosis of 'atelectasis of the left lung'. When the result of the sputum came back from the IPC, she was traced to her village and re-admitted to Takeo Provincial Hospital. She had not gone to Phnom Penh as she felt too weak and did not have the money. She was sitting on a bamboo bed under her house where her relatives would carry her for the day. She had an infection of her right knee and needed support when walking. She was re-

admitted and started on trimethoprim–sulphamethoxazole, chloramphenicol and doxycycline. She improved on this regimen: her cough subsided, she did not feel dyspnoeic anymore and weighed 37 kg on discharge. Her chest X-ray taken before discharge (Figure 2B) did not show the fast improvement of case 1, but this is not surprising as she had suffered lung infections for more than 10 years. She was also sent home with trimethoprim–sulphamethoxazole and doxycycline and was requested to return in 3 weeks for control and refill of medication.

#### 4. Discussion

Melioidosis is diagnosed in all countries surrounding Cambodia. The climate and environmental conditions in these countries are very similar (not considering the northern parts of Laos and Vietnam, which have four seasons). Also, the living and working conditions of the rice farmers in the villages in the lowlands of Cambodia are similar to those living in comparable situations in the surrounding countries – Thailand, Laos and Vietnam – while exposure of the farmers and their family members to surface water and mud is extensive. It is therefore very likely that melioidosis is present in the soil and surface water in Cambodia and that melioidosis infections occur in the rural population. The two primary reasons why melioidosis is under-diagnosed in Cambodia are (i) laboratories in the public hospitals are not equipped to grow the bacterium (at present the diagnosis can be made in only three facilities in the country: the IPC and Center of Hope in Phnom Penh, and Angkor Hospital for Children in Siem Reap), and (ii) clinicians working in the public hospitals are not yet familiar with melioidosis.

As the pulmonary form of melioidosis mimics TB, it is often misdiagnosed as pulmonary TB. With its ultimate wide clinical spectrum from sub-clinical to a fulminant infection with fatal outcome in 48 h, with the incubation period varying between 2 d and multiple years, and knowing that it can produce abscesses in all organs of the body, clinicians in Cambodian hospitals need to consider melioidosis in almost every differential diagnosis of patients with a febrile disease, especially if the patient

has one of the diseases that are known to predispose them to developing melioidosis. Various publications report on the most common presentations of infections with melioidosis.<sup>2-4</sup> How often melioidosis will be the final diagnosis, filtered out of the differential diagnoses, remains to be seen. For the moment it is not known how much melioidosis is a public health issue for Cambodia.

It is not often stressed, but as melioidosis tends to imitate other diseases, a proper history taking can be of importance to get to the diagnosis of melioidosis. Typical stories, like that of a near-drowning, a recent accident with the patient ending up in the water, a (burn) wound exposed to soil and/or surface water, etc., can put the treating clinician on the right track.

*Burkholderia pseudomallei* is reported to be 'ubiquitous' in surface water and wet soils in Southeast Asia, but it remains to be seen what 'ubiquitous' means for Cambodia, as studies have shown that there are wide variations in the percentage of surface water where *B. pseudomallei* can be cultured from. We do not know yet if the situation in Cambodia is more like that in northeastern Thailand,<sup>5</sup> where it could be isolated from 50% of the rice fields investigated, or comparable to that of Vietnam,<sup>6</sup> where the bacteria could be identified in a much lower percentage from rice fields surveyed around Ho Chi Min City. It is also to be seen what variations exist between provinces.

Surveys<sup>1</sup> have shown that the Cambodians suffer much more from diabetes (which is identified as the most common underlying condition in patients with melioidosis in Thailand) than populations in the surrounding countries. Yajnik (2004)<sup>7</sup> provides a critical evaluation of the different factors postulated to explain the rapidly increasing epidemic of type 2 diabetes in Asian countries: genetic, foetal, postnatal and adult components all appear to contribute.

Melioidosis might prove to be a significant public health issue in Cambodia. It can therefore be anticipated that when microscopic diagnostic possibilities become more widely available, *B. pseudomallei* will be relatively more frequently detected as a causative agent of community-acquired infections, with diabetes as underlying predisposing factor. The incidence and case-fatality rate of melioidosis will also depend on the amount and virulence of the *B. pseudomallei* strains present in the surface water and wet soil in Cambodia. The patients in this case report were lucky to be included in the surveillance study and could therefore be traced for proper treatment. However, many other patients are also probably suffering from one of the various forms of melioidosis and are going undiagnosed and may finally succumb.

The IPC-initiated surveillance of pneumonias in Takeo Provincial Hospital will provide the first reliable information from a public hospital on how often melioidosis is the cause of infection amongst patients presenting with pulmonary infections. The surveillance is planned to continue for 4 years, so more cases of pulmonary melioidosis can be expected during this time. Although it is not certain that case 2 suffered from pulmonary melioidosis for 10 years, the case illustrates very clearly the implications of clinicians not being familiar with the disease and the high prevalence of TB in Cambodia.

Cambodia is 'virgin territory' when it comes to knowledge of the prevalence of melioidosis, the spread and

virulence of *B. pseudomallei* in the environment, and the immunological response<sup>8</sup> of Cambodians to infection with *B. pseudomallei*. It will take many years and significant efforts by the Ministry of Health and supporting institutions before the importance of melioidosis as a public health issue in Cambodia will become clearer. But with all the knowledge and experience that has accumulated in countries such as Thailand and Australia, this will hopefully take place faster in Cambodia. Assistance by, and cooperation with, specialists and institutions in these countries would benefit this process of filling in the blanks in the 'melioidosis map' of Cambodia.

In the meantime, the initiative of the Pasteur Institute to provide possibilities to diagnose melioidosis to the clinicians in the public hospitals in the provinces, combined with activities to make these clinicians knowledgeable about the disease, will provide further information on the existence of melioidosis in the different provinces of Cambodia. At the same time, it is absolutely necessary that clinical personnel in the hospitals in Cambodia understand melioidosis and start to consider the disease in their differential diagnoses, especially for pulmonary TB, and for almost all other febrile infections, particularly during the rainy season. With this report, by organizing talks for clinical personnel in public hospitals, and publication in the Cambodian medical journal *Health Messenger*, we hope to increase the awareness of this disease amongst the clinicians in Cambodia's public hospitals.

**Authors' contributions:** RO was instrumental in the implementation of the surveillance, traced the patients, advised the clinicians regarding patient management and wrote the paper; VK assisted in the collection of patient data and was involved in the organization of the surveillance; PC was responsible for the implementation of the surveillance system; SH and BG isolated and identified the *B. pseudomallei* in the specimen of the two patients; VT, SC and PL were involved in the surveillance and treatment of the patients; SV had overall responsibility for the surveillance project and assisted with the writing of the paper. All authors reviewed the draft of the manuscript and read and approved the final version. SV is guarantor of the paper.

**Funding:** The study on the aetiologies of acute respiratory infections in Takeo hospital was sponsored by the French Agency for Development.

**Conflicts of interest:** None declared.

**Ethics approval:** The surveillance study was approved by the Cambodian National Ethics Committee and the Pasteur Institute-Paris Internal Review Board.

## References

1. King H, Keuky L, Seng S, Khun T, Roglic G, Pinget M. Diabetes and associated disorders in Cambodia: two epidemiological surveys. *Lancet* 2005;**366**:1633-9.
2. White NJ. Melioidosis. *Lancet* 2003;**361**:1715-22.
3. Currie BJ, Fisher DA, Howard DM, Burrow JNC, Lo D, Selva-Nayagam S, et al. Endemic melioidosis in tropical northern Australia: a 10-year prospective study and review of the literature. *Clin Infect Dis* 2000;**31**:981-6.

4. Chaowagul W, White NJ, Dance DA, Wattanagoon Y, Naigowit P, Davis TM, et al. Melioidosis: a major cause of community-acquired septicemia in northeastern Thailand. *J Infect Dis* 1989;**159**:890–9.
5. Wuthiekanun V, Smith MD, Dance DAB, White NJ. The isolation of *Pseudomonas pseudomallei* from soil in Northeastern Thailand. *Trans R Soc Trop Med Hyg* 1995;**89**:41–3.
6. Parry M, Wuthiekanun V, Hoa NTT, Diep TS, Thao LTT, Loc PV, et al. Melioidosis in Southern Vietnam: clinical surveillance and environmental sampling. *Clin Infect Dis* 1999;**29**:1323–6.
7. Yajnik CS. A critical evaluation of the fetal origins hypothesis and its implications for developing countries. *J Nutr* 2004;**134**:205–10.
8. Dance DAB. Melioidosis. *Curr Opin Inf Dis* 2002;**15**: 127–32.